


## Single-centre experience with mechanochemical ablation of insufficient veins with the **Flebogrif**<sup>®</sup> catheter in a 36-month follow-up.

Marek Iłżecki, Piotr Terlecki, Stanisław Przywara, Tomasz Zubilewicz  
Department of Vascular Surgery and Angiology, Medical University of Lublin, Lublin, Poland  
Phlebological Review 2021; 29, 1: 32–37

Published Online: 2021/06/1 | <https://doi.org/10.2217/fca-2020-0171>



### Introduction

**Flebogrif**<sup>®</sup> is the youngest representative of the MOCA treatment group. Its minimally invasive nature and high effectiveness contribute to its popularity. In the presented study, its effectiveness was assessed over a 36-month follow-up.

### Material and methods

Observations were conducted over a 36-month period as a prospective study. Two hundred patients meeting the established inclusion criteria were enrolled in the study, including 170 women aged 18 to 87, mean age 56 years, and 30 men, age 23 to 75, mean age 46 years. The obtained numerical data were statistically analysed using tests for variables with nonparametric distribution: Wilcoxon test and Friedman's ANOVA. The follow-up visits were scheduled as follows: baseline, 1, and 4 weeks and 3, 6, 12, 24, and 36 months. Numerical data were collected based on the assessment validation of venous clinical severity score (VCSS) and visual analogue scale (VAS). Ultrasound evaluation was performed to assess the anatomical effectiveness of the procedure. The safety of the method was assessed in terms of the severity and number of complications.

### Results

Based on the VCSS and VAS scale assessment, **a statistically significant decrease in the intensity of clinical symptoms was observed** both between monitoring visits and in relation to the baseline. One case of deep vein thrombosis (0.5%), 1 prolonged pain, 35 thrombophlebitis, and 28 discolourations (32%) were reported. **The 12-month success rate dropped to 92% and remained there until 36 months.**

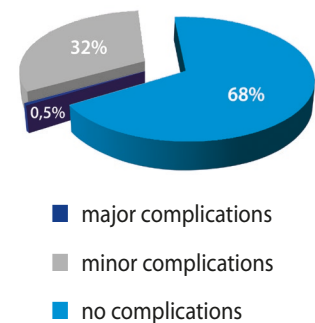
# Single-centre experience with mechanochemical ablation of insufficient veins with the **Flebogrif®** catheter in a 36-month follow-up

Marek Iłżecki, Piotr Terlecki, Stanisław Przywara, Tomasz Zubilewicz  
 Department of Vascular Surgery and Angiology, Medical University of Lublin, Lublin, Poland  
 Phlebological Review 2021; 29, 1: 32–37

Published Online: 2021/06/1 | <https://doi.org/10.2217/fca-2020-0171>

## Safety and surveillance

SAFETY	Major complications	DVT, PE, skin necrosis, n. injury	1-case DVT – trombofilia		
	Minor complications	Hyperpigmentation, haematomas, infection at the puncture site, ecchymosis, prolonged pain, induration, mild tension	1-case Prolongated pain	35-cases thrombophlebitis	28-cases discoloration
	Sclerosant (Polidocanol) – related side effects	Allergic reaction, effects of extravascular administration (pain, nerve injury, necrotic changes)	none		



Safety analysis of the MOCA method using the Flebogrif® catheter during the 36-month follow-up, it showed one case of deep vein thrombosis (DVT) among serious complications. In the course of further diagnostics, the patient was diagnosed with factor V Leiden mutation. The patient underwent anticoagulant therapy with NOAC drugs. Among minor complications, there was 1 case of prolonged pain, 35 cases of superficial vein thrombosis, and 28 cases of hyperpigmentation. No adverse effects related to the type of sclerosing agent used were observed.

## Conclusions

A high success rate of 92% was achieved, which is comparable with other methods currently used in the ablation of insufficient superficial veins. High safety of the method and low number of complications is expressed. Good cosmetic effect. A quick return to previous physical activity is an additional incentive for its use.

